

## IN THIS ISSUE:

## SPECIAL FEATURE

**1 Management of the Difficult Cataract in Glaucoma Patients**

*Tarun Sharma, MD, FRCSEd; Gus Gazzard, MA, MD, FRCOphth; and Keith Barton, MD, FRCP, FRCS, FRCOphth*

## UPDATE

**5 Technical Approaches to Combined Cataract and Glaucoma Surgery**

*Franz Grehn, MD*

## CLINICAL FOCUS

**7 Cataract & Glaucoma Surgery: Combined or Sequential?**

*Mark B. Sherwood, MD*

## IN PRACTICE

**8 Cataract Surgery and Glaucoma Control**

*Robert L. Stamper, MD*

## TARGET AUDIENCE

This educational activity is intended for general ophthalmologists, glaucoma specialists, and resident ophthalmologists.

## LEARNING OBJECTIVES

- Discuss the specific risks of cataract surgery in glaucomatous eyes and state strategies to manage those risks.
- List the surgical techniques that can be employed for improving outcomes in combined cataract and glaucoma surgery.
- List the conditions under which a combined glaucoma/ cataract procedure is preferred to sequential surgeries.
- State the effect of cataract surgery upon intraocular pressure in glaucomatous eyes.

## EDITORS

**Clive Migdal, MD, FRCS, FRCOphth**  
Western Eye Hospital, London, UK

**George A. Cioffi, MD**  
Devers Eye Institute,  
Portland, OR, USA

**Ivan Goldberg, MB, FRANZCO, FRACS**  
Sydney Eye Hospital, Sydney, NSW,  
Australia

GLAUCOMA TOPICS & TRENDS is published quarterly by Ethis Communications, Inc. and the University of Florida School of Medicine. This publication is administered by an independent editorial board and supported by an unrestricted educational grant from Allergan, Inc.

Copyright 2008 Ethis Communications, Inc. All rights reserved. Neither the University of Florida nor Ethis Communications, Inc. assume any responsibility for injury or damage to persons or property arising from the use of information or ideas contained in this publication.

## COURSE DIRECTOR

**M. Fran Smith, MD**  
University of Florida, Gainesville, FL, USA

**UF** Continuing  
Medical Education  
UNIVERSITY OF FLORIDA

# GLAUCOMA

## TOPICS & TRENDS

### GLAUCOMA AND CATARACT

## SPECIAL FEATURE

## Management of the Difficult Cataract in Glaucoma Patients

*Tarun Sharma, MD, FRCSEd, Gus Gazzard, MA, MD, FRCOphth; and Keith Barton, MD, FRCP, FRCS, FRCOphth*

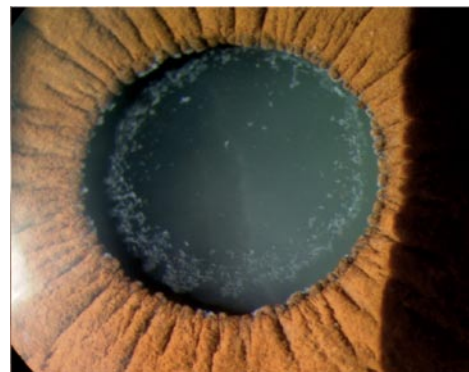**Advances in cataract surgery have come rapidly since the adoption of phacoemulsification, which offers surgeons greater control over the procedure. As a result, management of difficult cataracts (eg, in eyes with pseudoexfoliation syndrome, zonular instability, miosis, shallow anterior chambers, and/or subluxated lenses) has improved. Today, capsular dyes have improved visualization of the anterior capsule; there are better mechanical means of pupillary dilation; we have improved viscoelastics; we can access higher vacuum, with reduced total energy delivered during surgery; and we maintain chamber stability better with improved fluidics.**

### Small Pupils

Successful cataract surgery requires good access. While phacoemulsification might be possible through a poorly dilated pupil and a marginally adequate capsulorrhexis, these do not allow optimal control, especially in difficult cases (Figure 1). Miosis reduces visualization, often results in a smaller capsulorrhexis with increased risk of anterior capsule damage and increased capsular stress; there is increased risk of iris trauma with resultant inflammation, difficulty identifying residual cortical matter, and reduced ability to quickly recognize a posterior capsule tear.<sup>1</sup>

Small pupils can be managed in a variety of safe, quick, and practical ways (Table 1).<sup>2,3</sup> In

a recent comparison of four methods of pupil dilation, the authors found that, although time-consuming, iris-retractor hooks and a PMMA pupil-dilator ring were the most effective systems for maximizing pupil size.<sup>4</sup> These are good choices for eyes that require a pupil diameter of 5.5 mm or more. Of the devices studied, the pupil-dilator ring caused the least iris trauma. The authors noted that the Beehler pupil dilator and bimanual stretching were also effective, as well as quick and easy to perform.



**FIGURE 1** Small pupil in a patient with pseudoexfoliation syndrome after maximum pharmacological dilation.

In our experience, iris hooks are among the most effective and safest methods to increase pupil size. They work even with small, rigid pupils, and we find that we are increasingly using them during phacoemulsification surgery. However, any iris manipulation will increase breakdown of the blood-aqueous barrier, increasing post-

# GLAUCOMA TOPICS & TRENDS

## STATEMENT OF NEED AND PROGRAM DESCRIPTION

Recent months and years have seen significant advances in our understanding of glaucoma. Much has been learned, not only about damage mechanisms and pathogenesis, but also about diagnosis and management. Treatment options—both medical and surgical—continue to expand. This program will review this new knowledge with an emphasis on incorporating recent insights into day-to-day practice.

**GENERAL INFORMATION** In order to receive CME credit, participants should read the report, and then fill out the included paper test, or go to our online test engine at: <http://cme.ufl.edu/selfstudy/glau/>. After completing the posttest, a score of 80% is required to qualify for CME credit. You will be able to print your certificate at the completion of the posttest. There is no fee to participate in this activity. Estimated time to complete the activity is 60 minutes.

**DATE OF ORIGINAL RELEASE** June 2008. Approved for a period of 24 months.

**ACCREDITATION STATEMENT** This activity has been planned and implemented in accordance with the Essential Areas and Policies of the Accreditation Council for Continuing Medical Education (ACCME) through the joint sponsorship of the University of Florida College of Medicine and Ethis Communications, Inc. The University of Florida College of Medicine is accredited by the ACCME to provide continuing medical education for physicians.

**CREDIT DESIGNATION STATEMENT** The University of Florida College of Medicine designates this educational activity for a maximum of 1 *AMA PRA Category 1 Credit(s)*<sup>™</sup>. Physicians should only claim credit commensurate with the extent of their participation in the activity.

**DISCLAIMER** Participants have an implied responsibility to use the newly acquired information to enhance patient outcomes and professional development. The information presented in this activity is not meant to serve as a guideline for patient care. Any procedures, medications, or other courses of diagnosis or treatment discussed or suggested in this activity should not be used by clinicians without evaluation of their patient's conditions and possible contraindications or dangers in use, applicable manufacturer's product information, and comparison with recommendations of other authorities.

**COMMERCIAL SUPPORTERS** This activity is supported by an educational grant from Allergan, Inc.

## FACULTY AND DISCLOSURE STATEMENTS

**FRANZ GREHN, MD**, is Professor and Chairman, Department of Ophthalmology, University Würzburg, Würzburg, Germany. He states that neither he nor a spouse has or has had in the previous 12 months any financial arrangement with the manufacturer or provider of any product and/or service discussed in his article.

**Mark B. Sherwood, MD**, is Professor of Ophthalmology and Director of the Center for Vision Research at the University of Florida, Gainesville FL.

**Robert L. Stamper, MD**, is Professor of Clinical Ophthalmology and Director of the Glaucoma Service at University of California, San Francisco. He states that neither he nor a spouse has or has had in the previous 12 months any financial arrangement with the manufacturer or provider of any product and/or service discussed in his article.

**Tarun Sharma, MD, FRCSEd**, is Glaucoma Consultant at the Worcester Royal Hospital in Worcester, UK. He states that neither he nor a spouse has or has had in the previous 12 months any financial arrangement with the manufacturer or provider of any product and/or service discussed in his article.

**Gus Gazzard, MA, MD, FRCOphth**, is the Consultant Ophthalmic Surgeon, King's College Hospital, London, UK. He states that neither he nor his spouse has or has had in the previous 12 months any financial arrangement with the manufacturer or provider of any product and/or service discussed in his article.

**Keith Barton, MD, FRCP, FRCS, FRCOphth**, is Consultant Ophthalmologist at Moorfields Eye Hospital, London, UK. He states that neither he nor a spouse has or has had in the previous 12 months any financial arrangement with the manufacturer or provider of any product and/or service discussed in his article.

**TABLE 1 Strategies to Increase Pupil Size**

### Preoperative

- ◆ Pharmacological
  - Cycloplegics
  - Mydriatic
  - Topical NSAID

### Intraoperative

- ◆ Sphincter sparing
  - Intracameral adrenaline: 0.1 cc of 1:10,000 unpreserved adrenaline
  - Viscomydrisis: Ophthalmic viscodissection: Healon GV/Healon 5
  - Synaechiolysis
- ◆ Sphincter involving
  - Mechanical stretch
    - Two-instrument pupil stretch
    - Two-pronged pupil stretcher (Keuch Pupil Dilator)
    - Three- or four-pronged pupil stretcher (Beehler Pupil Dilator)
    - Pupil expanders: The perfect pupil, Graether pupil expander, morcher expansion ring, Siepser hydrogel ring
    - Pupil Dilator, iris hooks/retractors: Mackool (titanium), Dejuan (nylon)
  - Incisional mydriasis
    - Sphincterotomies
    - Iridectomy

counter-traction and tautens the posterior capsule so that the circular contour of the capsular bag is maintained, enhancing zonular support and creating better centration.

In eyes with traumatic lens subluxation, these techniques may allow successful cataract removal, as the remaining zonules may provide enough support. In severe pseudoexfoliation, the remaining intact zonules are often very weak; perhaps consider intracapsular cataract surgery.

## Managing Subluxated Cataracts

**Wound placement** Site the corneal or scleral tunnel away from the area of zonular weakness. If hooks and a ring can stabilize the capsular bag adequately, use your preferred site of incision. Make the initial entry into the anterior chamber just large enough to insert the viscoelastic cannula; Use an appropriate volume of cohesive viscoelastic over the area of zonular dialysis. Avoid overfilling the chamber with viscoelastic to minimize stress on the already weakened zonules.

**Capsulorrhexis** Weak zonules make capsulorrhexis a major challenge, but it is a prerequisite for CTR placement. Capsular dyes are safe and effective as an adjunct for capsule visualization.<sup>13</sup> Currently, only trypan blue is approved for use in cataract surgery.<sup>13</sup> Initiate the capsulorrhexis in an area away from the dialysis so that the intact zonules can provide necessary counter-traction.

Iris retractors ensure an adequately sized capsulorrhexis with subluxated cataracts with small pupils.<sup>14</sup> The capsulorrhexis should be large over the area of intact zonules and less peripheral at the site of the defect, as there is a higher chance of a capsulorrhexis tearing out peripherally in the area of zonular weakness.

**Hydro-dissection** Inject small amounts of fluid in different quadrants, to minimize anterior chamber shallowing following hydro-dissection. Ensure the hydro-dissection is complete and the nucleus mobile before phacoemulsification to minimize zonular stress from nuclear rotational forces.

operative inflammation. In such cases additional postoperative topical corticosteroids are usually required.

## Phacoemulsification of Subluxated Lenses

Weak or absent zonules present a serious challenge. Every step of the procedure is more challenging than in normal phacoemulsification. There is increased risk of capsule rupture, vitreous prolapse, retained lens material, and postoperative dislocation of the intraocular lens (IOL). The capsular bag can be stabilized either equatorially with a capsular tension ring (CTR), a concept introduced in 1991 by Hara et al, or by anterior-posterior stabilization using capsule/iris retractors.<sup>5,6</sup>

Selection of an appropriate-size CTR is based on capsular bag dimensions; in most cases, a larger CTR is preferred.<sup>8</sup> At present, a number of capsular bag support devices are available (Table 2).<sup>9-12</sup>

When properly placed, the CTR expands the capsular equator and buttresses the area of poor zonular support, providing relatively equal distribution of stress over the remaining zonules. The ring provides

# SPECIAL FEATURE

**Phacoemulsification** Prior to phacoemulsification, minimize stress to the zonules by stabilizing the capsular bag with a CTR and capsular hooks.<sup>15</sup> Reduce bottle height by about 10-15 cm from normal to ease anterior-posterior pressure on the weak zonules. Take care: there is risk in both too high and too low bottle heights. If the bottle is too low, there will be insufficient irrigation and greater risk of surge and chamber instability. Higher bottle heights cause high inflow rates, which can force fluid through the area of zonular dialysis, leading to vitreous hydration that, in turn, causes positive vitreous pressure, anterior chamber shallowing, and vitreous prolapse. On balance, vacuum and flow rates are best reduced by about 20% to avoid surge and iris flicker.

With a phaco-chop technique there is reduced stress on the zonules and capsular bag, and chopping into small fragments improves follow-ability. Prior to withdrawing irrigation, inject viscoelastic through the paracentesis to minimize the forward trampolining of the capsular bag and vitreous prolapse.

A CTR makes cortex aspiration more difficult, as it sandwiches the cortex between ring and capsular bag. To remove the cortex, move the irrigation-aspiration tip in a tangential manner, removing cortex in very small amounts. In cases of severe subluxation, manual cortex aspiration is preferred.

**Capsular Phimosis** Capsular phimosis is a postoperative concern despite CTR implantation. Capsular contraction forces may be symmetrical or asymmetrical. Asymmetrical forces are the more worrisome, as these can shift the IOL to one side (usually the stronger side). Symmetrical contraction, on the other hand, is less likely to de-center the lens. To reduce the risk of

capsule contraction syndrome, some advocate aspiration of lens epithelial cells on the under surface of the anterior capsule. This reduces lens epithelial cell proliferation and metaplasia.

To prevent de-centration, consider anterior capsule-relaxing incisions, either intraoperatively with micro-scissors or postoperatively with an Nd:YAG laser anterior capsulotomy.

## Shallow Anterior Chamber

When operating on an eye with a shallow anterior chamber and/or a short axial length, it is useful to reduce the intraocular pressure (IOP) prior to surgery by either massage or application of a Honan balloon. Both methods usually soften the eye and, after the injection of viscoelastic into the anterior chamber, facilitate surgical manipulation of the anterior segment. Take particular care with ocular compression techniques in eyes with advanced glaucomatous optic neuropathy.

Depending on the axial length or anterior chamber depth, consider planned posterior segment decompression, especially if viscoelastic injection does not permit sufficient anterior chamber deepening to allow easy instrument maneuver in the anterior segment.

Anterior chamber depth can be maintained with new visco-adaptive agents, such as Healon5®. These agents also ensure anterior chamber stability during creation of the wound and capsulorrhexis. Alternatively, use an anterior chamber maintainer.

Pay attention to wound construction in these cases. In shorter eyes, a longer, shelved corneal wound placed more anteriorly helps to avoid iris prolapse, while maintaining anterior chamber stability throughout the procedure.

## Core Concepts

- Cataract surgery in glaucomatous eyes may entail more risk than in normal eyes. Anticipate potential problems with a careful preoperative clinical exam and plan an avoidance strategy.
- Patients need to understand their increased risk.
- Cataract surgery may upset control of otherwise stable glaucoma or reduce the function of a pre-existing trabeculectomy. Frequent postoperative monitoring is often required.
- Technological innovations, such as viscoelastics and CTRs offer a greater degree of control during cataract surgery.
- When cataract surgery is likely to be complex, combined procedures such as phaco plus trabeculectomy are best avoided.

Quick chop is a useful technique. Keep the phaco tip in the bag or at the iris plane throughout, as this minimizes thermal damage to the corneal endothelium. Be cautious regarding the posterior capsule and consider raising the bottle height to increase the anterior chamber depth.

Regardless of the phacoemulsification system employed, adjust the parameters (particularly flow and vacuum settings) to maintain stability of the anterior chamber and posterior capsule. Avoiding chamber surge and bounce reduces the likelihood of posterior capsular tears. Aspirate cortex in

**TABLE 2 Various Types of Capsule Bag Support/Capsule Tension Rings**

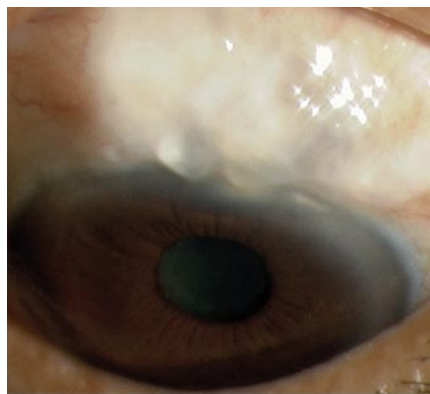
Type	Size in mm	Indication	Insertion Time	Comments
Capsule tension ring (CTR)	3 sizes L 14:12 M13:11 S 12:10	Mild zonular (<4 clock hours with intact CCC and capsule)	Any time after CCC	Compressible circular open PMMA ring
Modified Capsular Tension Ring (MCTR)	Single size with 1 or 2 fixation eyelets	Moderate to severe zonular weakness with adequate size CCC (5.5 mm)	After removal of nucleus and cortex	Anchors capsular bag to sclera, offering better centration and stability of capsular bag
Capsular Tension Segment (CTS)	4.75/5.0/5.5	Profound zonular weakness	Before nucleus removal	Partial PMMA ring Can be used with discontinuous CCC and posterior capsule tear Can be used alone or in combination with CTR/ MCTR

CCC = continuous curvilinear capsulorrhexis (CCC)

a controlled manner by raising the bottle height to a level that maintains anterior chamber stability and reduces posterior capsule fluctuations. After inserting the IOL, use Miochol®-E to constrict the pupil and move the iris away from the wound. Check the incision to verify there is no leak and to ensure maintenance of proper anterior chamber depth.

## Pseudo-exfoliation syndrome

Patients with pseudo-exfoliation syndrome have reduced endothelial cell counts, poor mydriasis, brittle lens capsules, harder nuclei (requiring increased emulsification time), compromised zonules, and increased incidence of postoperative inflammation and glaucoma.<sup>16-17</sup> Clinical difficulties arise from zonular weakness at the level of the fibers or their insertions into either the lens or the non-pigmented ciliary body epithelium.



**FIGURE 2** Pre-existing bleb in an eye with pseudo-exfoliation syndrome and weak zonules. This eye represents a significant surgical challenge.

Rotational and anterior-posterior forces created during nucleus emulsification may lead to total separation of weakened zonules, with vitreous loss, increased complexity of surgery and risk of complications.<sup>17-18</sup> Improved fluidics of new-generation phacoemulsification machines cause less fluctuation in anterior chamber, depth, placing less stress on the zonules.<sup>17-18</sup>

In pseudo-exfoliation syndrome, poor mydriasis, shallow anterior chamber and a pseudo-elastic anterior capsule appearance caused by zonular weakness all hamper initiation and completion of the capsulorhexis.<sup>18</sup> Manage poor mydriasis by the techniques described above. An adequately sized capsulorhexis is very important in eyes with exfoliation syndrome to minimize zonular

stress during later stages of surgery.

**Hydrodissection** A cortex-cleaving hydro-dissection with gentle decompression at the center of the lens helps minimize (further) unzipping of the zonules.<sup>19</sup> This can be done at multiple points. Hydro-delineation helps to confirm the size of the nucleus, to help to determine whether trenching or horizontal chopping is easier.

**Capsular Bag Stabilization** Stabilize the capsular bag with a CTR as described above.

**Phacoemulsification** Chopping is better than grooving and cracking. Trenching procedures result in the entire force being directed downward, placing more stress on the zonules and capsular bag whereas chopping results in more pressure on the nucleus. Kelman tips may offer an advantage as they obliterate nuclear material in advance of the tip without exerting force on the lens or the zonules. Adequate power will minimize stress on the zonules through traction exerted on the nucleus. Reduce vacuum and flow rate for better anterior chamber stability.

The zonules are at maximum stress during cortical aspiration. With a CTR, tangential movements also help dislodge the cortical fibers trapped between the CTR and the bag. The direction of cortical removal should be towards the area of greatest zonular deficiency to prevent further unzipping. Unrelenting zonular stress from capsule phimosis may be a factor in late IOL/capsule subluxation or dislocation and may occur even in the presence of a CTR.<sup>20</sup>

*Tarun Sharma, MD, FRCSEd, is a Glaucoma Consultant at the Worcester Royal Hospital in Worcester, UK. Gus Gazzard, MA, MD, FRCOphth, is the Consultant Ophthalmic Surgeon, King's College Hospital, London, UK. Keith Barton, MD, FRCP, FRCS, FRCOphth, is Consultant Ophthalmologist at Moorfields Eye Hospital, London, UK.*

## REFERENCES

1. Fine IH. Phacoemulsification in the presence of small pupil. In: Steinert RF, ed. *Cataract Surgery: Technique, Complications, and Management*. Philadelphia: WB Saunders, 1995:199-208.
2. Goldman JM, Karp CL. Adjunct devices for managing challenging cases in cataract surgery: capsular staining and ophthalmic viscosurgical devices. *Curr Opin Ophthalmol*. 2007;18(1):52-57.
3. Goldman JM, Karp CL. Adjunct devices for managing challenging cases in cataract surgery: pupil expansion and stabilization of the capsular bag. *Curr Opin Ophthalmol*. 2007;18(1):44-51.

4. Akman A, Yilmaz G, Oto S, Akova YA. Comparison of various pupil dilatation methods for phacoemulsification in eyes with a small pupil secondary to pseudoexfoliation. *Ophthalmology*. 2004 Sep;111(9):1693-98.
5. Sun R, Gimbel HV. In vitro evaluation of the efficacy of the capsular tension ring for managing zonular dialysis in cataract surgery. *Ophthalmic Surg Lasers*. 1998;29:502-05.
6. Ciooni RJ, Usher RH. Management of profound zonular dialysis or weakness with new endocapsular ring designed for scleral fixation. *J Cataract Refract Surg*. 1998;24: 1299-1306.
7. Hara T, Hara T, Yamada Y. Equator ring for maintenance of the completely circular contour of the capsular bag equator after cataract removal. *Ophthalmic Surg*. 1991;22:358-59.
8. Ahmed IK et al. Capsular tension rings. Update on endocapsular support devices. *Ophthalmol Clin North Am*. 2006;19:507-19.
9. Ahmed IK, Cionni RJ, Kranemann C, et al. Optimal timing of capsular tension ring implantation: a Miyake-Apple video analysis. *J Cataract Refract Surg*. 2005;31:1809-13.
10. Cionni RJ, Osher RH. Management of profound zonular dialysis or weakness with a new endocapsular ring designed for scleral fixation. *J Cataract Refract Surg*. 1998;24:1299-1306.
11. Ahmed IK, Butler M. Capsular tension devices for the glaucoma surgeon. *Glaucoma Today*. 2004; Nov-Dec:1-4.
12. Gimbel HV, Sun R, Heston JP. Management of zonular dialysis in phacoemulsification and IOL implantation using the capsular tension ring. *Ophthalmic Surg Lasers*. 1997;28:273-81.
13. Jacobs DS, Cox TA, Wagoner MD, et al. Capsule staining as an adjunct to cataract surgery. A report from the American Academy of Ophthalmology. *Ophthalmology*. 2006;113:707-13.
14. Merriam J, Zheng L. Iris hooks for phacoemulsification for the subluxated lens. *J Cataract Refract Surg*. 1997;23:1295-97.
15. Gimbel HV, Sun R, Heston JP. Management of zonular dialysis in phacoemulsification and IOL implantation using the capsular tension ring. *Ophthalmic Surg Lasers*. 1997;28:273-81.
16. Schlötzer-Schrehardt UM, Koca MR, Naumann GOH, et al. Pseudoexfoliation syndrome: ocular manifestation of a systemic disorder? *Arch Ophthalmol*. 1992;110:1752-56.
17. Dossa AA, Bonvin ER, Leuenberger PM. Exfoliation syndrome and phacoemulsification. *J Cataract Refract Surg*. 1997;23:122-25.
18. Kuchle M, Viestenz A, Martus P, et al. Anterior chamber depth and complication during cataract surgery in eyes with pseudoexfoliation. *Am J Ophthalmol*. 2000;129:281-85.
19. Fine IH. Cortical cleaving hydrodissection. *J Cataract Refract Surg*. 1992;18:508-12.
20. Jehan FS, Mamalis N, Crandall AS. Spontaneous late dislocation of intraocular lens with the capsular bag in pseudoexfoliation patients. *Ophthalmology*. 2001;108:1727-31.

**For back issues of**  
**GLAUCOMA**  
**TOPICS&TRENDS**  
**visit**  
[www.GlaucomaTopics.com](http://www.GlaucomaTopics.com)

# Technical Approaches to Combined Cataract and Glaucoma Surgery

Franz Grehn, MD

**Chronic primary open-angle glaucoma (POAG) and cataract are slowly progressive conditions, showing increasing prevalence with advancing years. Both can cause vision loss and eventually blindness, although by very different means.**

Glaucoma is usually asymptomatic. Hence, the proportion of undetected chronic glaucoma is high and varies considerably between industrialized countries (detection rate approximately 50%) and developing countries (detection rate close to 10%). Cataract, on the other hand, is obvious to the patient. As a result, the incidence of visually disturbing cataract per year in developed countries is roughly the same as the number of cases operated per year.

## Indications

The decision to have combined cataract-glaucoma surgery vs sequential surgery vs either of these procedures alone depends on the individual case and on the patient's and surgeon's preferences.<sup>4,8,11,12,17</sup>

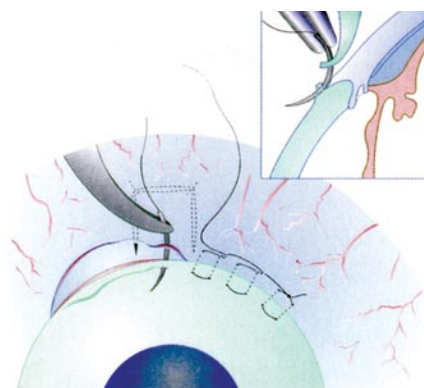
If the patient has visually significant cataract and ocular hypertension without glaucomatous vision loss, cataract surgery alone may lower intraocular pressure (IOP) significantly, often for several years. The more advanced the glaucoma, in terms of both optic nerve damage and IOP elevation, the more important surgical intervention to reduce IOP becomes. In this case, glaucoma surgery is indicated as a first step or in combination with cataract surgery. Because filtering surgery is more likely to fail when combined with cataract surgery than when performed alone, some surgeons restrict combined surgery to situations where neither the glaucoma nor the cataract surgery can be postponed.

Whenever sequential surgery is considered, the surgeon must decide which procedure to perform first. This decision is often determined by the need to control IOP and complicated by the fact that cataract surgery in eyes with functioning filtering blebs

may negatively affect IOP control.<sup>10</sup> Thus, in cases where cataract surgery is needed and IOP can be adequately controlled for a period of weeks by medication, cataract surgery may be performed first, with the glaucoma surgery performed as the second step. This can make it easier to control wound healing in the filtering bleb in the period after filtration surgery. When done in the reverse order, it may be more difficult to control problems with filter function after the second cataract surgery.

## Technique

**Glaucoma surgery** Conjunctival dissection at the limbus (fornix based) is preferred by many surgeons for both trabeculectomy alone and for combined glaucoma-cataract surgery (Figure 1). This approach reduces the stimulation of wound healing response at the level of the subconjunctival connective tissue.<sup>9,13</sup>



**Figure 1** Suture technique with a fornix-based conjunctival flap.

**Cataract technique** Clear corneal incisions are often preferred for the phacoemulsification portion of combined cataract-glaucoma surgery, as these incisions do not stimulate conjunctival fibroblasts. However, small corneoscleral incisions may be equally suited when performed at the site of glaucoma surgery.<sup>1,7,2,16</sup> Both techniques provide effective IOP reduction, with minimal stimulation of inflammation and wound healing processes.

## Core Concepts

- Combined cataract and glaucoma procedures are usually performed when there is a pressing need both to control IOP and to remove a visually significant cataract.
- If the surgeries can be performed sequentially, typically the cataract procedure is performed before the glaucoma surgery.
- Uncomplicated phacoemulsification surgery with a clear corneal incision may create problems with a previously functioning filtering bleb.
- Preventing an excessive wound-healing response in the area of the bleb is an important consideration in combined procedures.

## Sequencing of Procedures

In combined glaucoma-cataract procedures, most surgeons start with the cataract portion followed by the glaucoma surgery. If separate incisions are used for cataract and glaucoma, technical problems could arise from:

- A soft globe when cataract surgery with a clear corneal incision is completed first, making dissection of the scleral flap more difficult; or
- A ballooning filtering bleb due to excessive outflow during irrigation in the cataract part when glaucoma surgery is completed first. Therefore, some surgeons start glaucoma surgery with dissection of the conjunctiva and the scleral flap without penetration. This is followed by clear corneal incision cataract surgery, which is taken to completion. Only then is penetration at the site of filtration (trabeculectomy, punching, or goniotrephination) completed.<sup>2</sup> Many different glaucoma procedures can be combined with cataract surgery (Table 1).

## One-site vs Two-site Approaches

Formerly, when glaucoma surgery was performed in combination with extracapsular cataract surgery using a corneoscleral incision and a rigid IOL, the large wound could create excessive healing in the area of the filter. Today, with phacoemulsification

surgery and foldable lenses, the conjunctival wound is small. This allows the site of glaucoma surgery also to be used as the approach for phacoemulsification. There is no longer an excessive wound healing response.<sup>3,7,8,16</sup>

**TABLE 1 Glaucoma procedures that can be combined with cataract surgery**

- Trabeculectomy
- NPDS (Non-penetrating drainage surgery)
- Angle surgery
- Laser surgery
- Tube surgery
- Cyclodestructive procedures

**One-site approach** The scleral flap is dissected and a penetrating corneoscleral wound (2.8 mm wide) is made into the anterior chamber underneath the scleral flap for cataract surgery. After completing phacoemulsification and foldable lens implantation, the scleral opening is either excised from the same incision with a diamond blade or created with a punch.

**Two-site approach** This follows the idea that any additional intervention at the filtration site may create a greater (and unwanted) wound-healing response. Therefore, the clear corneal incision for phacoemulsification and lens implantation is positioned at the temporal site, and the filtration site is located at the 12:00 o'clock position.<sup>6,18</sup>

Several randomized prospective studies found a trend toward better outcomes with the two-site approach.<sup>2,6</sup> However, in none of these studies was the difference statistically significant, probably due to the insufficient number of cases followed.<sup>1,2,5,15,19</sup>

### Antimetabolites

Combined glaucoma-cataract procedures have a higher risk of excessive wound healing than glaucoma surgery alone. Many surgeons advocate preoperative anti-inflammatory treatment with topical steroids and wash out of glaucoma medications, which can mediate inflammation. Intraoperative antimetabolites considerably improve the success rate of the glaucoma part of the combined surgery. Mitomycin-C (0.2 to 0.5 mg/mL) can be applied topically for 3 to 5 minutes in a sponge laid over a large area.

Postoperative wound healing may be controlled by more frequent application of topical steroid drops. For intensified postoperative care, injections (5 mg) of 5-fluorouracil may be used, depending on the status of the filtering bleb.<sup>14</sup>

### Sequential Surgery

A number of recent studies have found that functioning filtering blebs may lose functionality following subsequent uneventful clear cornea phacoemulsification surgery.<sup>10</sup> In a prospective study using a control group of unoperated glaucoma cases matched for age and visual field damage, 1 year after clear cornea phacoemulsification a mean 2-mmHg increase in IOP was found in the operated eyes. In the control eyes, an average IOP decrease of 2 mmHg was found.<sup>10</sup> Fourteen of 30 eyes with functioning filtering blebs had an IOP increase of more than 2 mmHg after clear cornea phacoemulsification, whereas only four of 30 eyes had an IOP decrease of more than 2 mmHg. In the control group, six of 36 eyes had an IOP increase of more than 2 mmHg, whereas 13 of 36 eyes had an IOP decrease of more than 2 mmHg.

### Bleb Failure After Phacoemulsification

There is no established regimen for overcoming the unpredictable IOP increase that tends to occur after clear cornea phacoemulsification in eyes with a previously functioning filtering bleb. The topical corticosteroids routinely administered after cataract surgery are unlikely to cause long-term IOP increase. Nor is there any indication that factors are released from the lens during surgery that could stimulate excessive wound healing in this situation. Subclinical inflammation, however, may contribute to an ongoing scarring process. Some surgeons use repeated 5-fluorouracil injections after cataract surgery to compensate for the IOP increase following phacoemulsification in eyes with blebs that had functioned well before the cataract procedure.

### Conclusions

In general, the decision to proceed with combined glaucoma and cataract surgery is based on:

- the perceived need to treat both the cataract and glaucoma
- the risk entailed in postponing one of the procedures, or
- the comfort of the patient, particularly if the patient is elderly and would not tolerate two separate surgical interventions.

Typically, a combined procedure is indicated when there is urgent need for glaucoma surgery at the same time that visually disturbing cataract is present. On the other hand, if cataract surgery is not needed at the

point when glaucoma surgery is indicated, it should be postponed. When the glaucoma is mild or there is ocular hypertension without visual field defects, cataract surgery with phacoemulsification alone will provide some IOP lowering in many cases. The cataract surgery may also facilitate monitoring of the patient's glaucoma by allowing better visualization of the optic disk and more reliable visual field testing.

*Franz Grehn, MD, is Professor and Chairman, Department of Ophthalmology, University Würzburg, Würzburg, Germany.*

### REFERENCES

1. Allan BDS, Barrett GD. Combined small incision phacoemulsification trabeculectomy. *J Cataract Refract Surg.* 1993;19:97-102.
2. Borggreffe J, Lieb WE, Grehn F. A prospective randomized comparison of two techniques of combined cataract-glaucoma surgery. *Graefes Arch Clin Exp Ophthalmol.* 1999;237:887-92.
3. Cagini C, Murdolo P, Gallai R. Longterm results of one-site phacotrabeulectomy. *Acta Ophthalmol Scand.* 2003;81:233-36.
4. Cohn H. Combined cataract and glaucoma surgery. *J Fr Ophthalmol.* 2005;28:52-4.
5. El Sayyad F, Helal M, El Maghrabi A et al. One-site versus 2-site phacotrabeulectomy: a randomized study. *J Cataract Refract Surg.* 1999;25:77-82.
6. Gayton JL, Van der Karr MA, Sanders V. Combined cataract and glaucoma procedures using temporal cataract surgery. *J Cataract Refract Surg.* 1996;22:1485-91.
7. Gimbel HV, Meyer D. Small incision trabeculectomy combined with phacoemulsification and intraocular lens implantation. *J Cataract Refract Surg.* 1993;19:92-6.
8. Gregg FM. Phacoemulsification and modified trabeculectomy for managing combined cataracts and glaucoma. *J Cataract Refract Surg.* 1992;18:362-65.
9. Khaw PT. Advances in glaucoma surgery: evolution of antimetabolite adjunctive therapy. *J Glaucoma.* 2001;10:81-84.
10. Klink J, Schmitz B, Lieb WE, et al. Filtering bleb function after clear cornea phacoemulsification: a prospective study. *Br J Ophthalmol.* 2005;89:1245-59.
11. Longstaff S, Wormald RPL, Mazover A, et al. Glaucoma triple procedures: efficacy of intraocular pressure control and visual outcome. *Ophthalmic Surg.* 1990;21:786-93.
12. Mamalis N, Lohner S, Rand AN, et al. Combined phacoemulsification, intraocular lens implantation and trabeculectomy: *J Cataract Refract Surg.* 1996;22:467.
13. Mandic Z, Bencic G, Zoric-Geber M, et al. Fornix vs limbus based flap in phacotrabeulectomy with mitomycin C: prospective study. *Croat Med J.* 2004;45:275-78.
14. Marquardt D, Lieb WE, Grehn F. Intensified postoperative care vs conventional follow-up: a retrospective long-term analysis of 177 trabeculectomies. *Graefes Arch Clin Exp Ophthalmol.* 2004;242:106-13.

Additional references for this article can be found on [www.GlaucomaTopics.com](http://www.GlaucomaTopics.com)

# Cataract & Glaucoma Surgery: Combined or Sequential?

Mark B. Sherwood, MD

**Glaucoma and cataract are both common conditions in the elderly, and they frequently coexist in our patients. Surgery for one condition can affect the other. There is, for example, good evidence that trabeculectomy can increase the risk of cataract progression, and there is also evidence that the risk of bleb failure (or decreased bleb function) increases following phacoemulsification surgery in eyes with preexistent blebs.<sup>1,2</sup>**

While it is always appealing to solve two problems for a patient at one sitting and to spare the patient a second trip to surgery, the combined cataract and glaucoma procedure is longer and often more technically difficult than individual surgeries. In addition, although some patients have both a visually significant cataract and inadequately controlled intraocular pressure (IOP) despite maximal medical and laser therapy, more frequently there is asymmetry, with one of these conditions needing surgical intervention and the other, although present, not yet requiring an operation.

## Key Determinants

In patients with a visually significant cataract, the key determinants in deciding whether to perform a combined surgery or simple phacoemulsification with implantation of a posterior chamber intraocular lens (IOL) are:

- IOP level
- Number of medications needed to achieve this IOP level
- Limits to medication use, such as
  - Concerns about patient adherence to drop regimen
  - History of medication intolerance
  - Systemic disease that might limit future medication use
- How advanced the glaucomatous nerve damage is
- Patient's risk of late bleb infection given lid hygiene, etc.
- Age and general health of the patient
- Patient's preference for not taking glaucoma drops vs risks of having a bleb

## Advantages of a Combined Procedure

The main advantage of a combined procedure is the promise of acceptable IOPs for years without the need for glaucoma medications. In addition, patients with advanced glaucoma are at greater risk of field loss from a postoperative IOP spike, and the combined procedure may reduce the risk of an IOP spike in the period after surgery.

It must be kept in mind that phacoemulsification surgery alone will often reduce IOP and lessen the need for glaucoma medications. Not infrequently, patients who seem destined for eventual glaucoma surgery, if their current surgery is limited to phacoemulsification and posterior chamber IOL implantation do so well that they never need the glaucoma surgery.

More importantly, if successful, the combined procedure increases the long-term risk of bleb leak, blebitis, and endophthalmitis, which, in one study of trabeculectomy blebs, was seen in more than 20% of patients over a 5-year period.<sup>3</sup> This has encouraged some investigators to promote the use of nonpenetrating glaucoma procedures, such as deep sclerectomy and viscocanalostomy in combination with cataract surgery. The caveat is that, if the nonpenetrating procedure fails to provide adequate IOP control, the patient is at some disadvantage from having already had conjunctival surgery at the prime surgical site for a trabeculectomy.

## Bleb Survival and IOP Control

A key issue with combined procedures is their efficacy with respect to the final visual acuity result and, more importantly, bleb survival and IOP control. There is some evidence that trabeculectomy alone will produce slightly better IOP control than combined phacotrabeculectomy.<sup>4</sup> This may be related to the increased and prolonged ocular inflammatory response induced by the combined surgery. For those eyes with a trabeculectomy that later requires phacoemulsification, the bleb survival rate may not be very different from bleb survival

## Core Concepts

- Cataract and glaucoma are both common, but their presentation may be asymmetric.
- Combined and sequential phacoemulsification and trabeculectomy surgeries both have a high success rate for IOP control and good vision.
- Phacoemulsification surgery by itself can lower IOP and/or reduce medication needs in many patients.
- Trabeculectomy can help reduce the risk of early postoperative IOP spike and future glaucoma medication requirements but carries risks for late complications.

following a combined procedure, but not all patients will need the cataract surgery.

Although there is little good data in the literature, my personal preference for most unoperated eyes with both cataract and only moderately controlled glaucoma is to perform the procedures sequentially, with the phacoemulsification surgery first. Close postoperative IOP monitoring will determine whether trabeculectomy is needed. As long as there is not undue risk to the optic nerve, the surgeries should be separated by at least 3 to 6 months. This provides time for inflammation to resolve, increasing the chances of a successful bleb.

*Mark B. Sherwood, MD, is Professor of Ophthalmology and Director of the Center for Vision Research at the University of Florida, Gainesville FL.*

## REFERENCES

1. Husain R, Aung T, Gazzard G, et al. Effect of trabeculectomy on lens opacities in an East Asian population. *Arch Ophthalmol.* 2006;124:787-92.
2. Rebolledo G, Munoz-Negrete FJ. Phacoemulsification in eyes with functional filtering blebs: a prospective study. *Ophthalmology.* 2002;109:2248-55.
3. DeBry PW, Perkins TW, Heatley G, et al. Incidence of late-onset bleb-related complications following trabeculectomy with mitomycin. *Arch Ophthalmol.* 2002;120:297-300.
4. Singh RP, Goldberg I, Mohsin M. The efficacy and safety of intraoperative and/or postoperative 5-fluorouracil in trabeculectomy and phacotrabeculectomy. *Clin Experiment Ophthalmol.* 2001;29:296-302.

# Cataract Surgery and Glaucoma Control

Robert L. Stamper, MD

**It has been known for more than 40 years that cataract extraction can lower intraocular pressure (IOP) for prolonged periods. This IOP lowering is independent of the surgery procedure—it happens whether the cataract was removed by an intracapsular, extracapsular, or phacoemulsification technique, and it happens with or without intraocular lens implantation.<sup>1,2</sup> Following cataract surgery, both the IOP and the number of medications required are reduced, and the effect lasts as long as 5 years.<sup>3</sup>**

The clinical significance of the IOP drop has been difficult to determine, since the patients in most studies were also taking antihypertensive medications. Shingleton and coworkers found only a modest reduction in IOP, but the number of glaucoma medications patients had to take was reduced significantly.<sup>3</sup>

The effect in eyes with exfoliative syndrome seems to be slightly more pronounced and relatively longer lasting.<sup>4</sup> In eyes with angle closure glaucoma, the effect of cataract extraction on IOP also appears to be greater. In eyes with angle closure, cataract extraction alone can lower IOP for prolonged periods, and this is the case whether or not iridotomy was performed prior to cataract surgery.<sup>5,6</sup> In fact, phacoemulsification with lens implantation has been advanced as a treatment for acute angle closure glaucoma, although it may not be effective in eyes with plateau iris.<sup>7,8</sup>

## Postoperative IOP Elevation

In the first 24 hours after cataract surgery, transient IOP elevations occur in up

to 75% of glaucomatous eyes.<sup>9</sup> In addition, substantial IOP spikes may occur within the first 8 hours after surgery in 13% to 35% of eyes.<sup>10</sup> Timolol and other medications may blunt the pressure rises but will not eliminate them.<sup>11</sup> Patients whose IOP is elevated prior to surgery are at highest risk of a pressure spike.<sup>12</sup>

Hydroxypropylmethylcellulose viscoelastic appears to induce higher pressure spikes than sodium hyaluronate 1%.<sup>8</sup> Significant pressure spikes may be risk factors for further damage to the optic nerve or even ischemic optic neuropathy.

## Combined Surgery?

Cataract surgery alone can improve the patient's glaucoma status; it is, however, less effective than the combination of glaucoma filtration and cataract surgeries.<sup>13</sup> With cataract surgery alone there is the risk of a transient pressure elevation high enough to further injure an already damaged optic nerve. On the other hand, combined surgery risks hypotony and lower long-term efficacy than filtering surgery alone.

Therefore, if reduced vision (from the cataract) is the main problem, and the patient's glaucoma is relatively well controlled on medication and/or laser trabeculoplasty, then a simple cataract extraction/lens implantation procedure is a reasonable first step.<sup>14</sup> If, however, the glaucoma is sufficiently far advanced that transient IOP elevation could further compromise a very sick optic nerve, or if IOP control requires maximal tolerated medical therapy (and laser trabeculoplasty has been done), or if the IOP is uncontrolled on maximal medical therapy following laser trabeculoplasty, then either sequential surgery with glaucoma surgery first

## Core Concepts

- Cataract surgery alone can lower IOP in glaucomatous eyes.
- The effect of cataract surgery is greatest in eyes with exfoliative syndrome or angle closure.
- Cataract surgery causes transient IOP elevation in most glaucomatous eyes and very significant IOP spikes in a subset of these.
- These IOP spikes can be very damaging to glaucomatous eyes that have already sustained significant optic nerve damage from the disease.
- Cataract surgery alone has less IOP lowering effect than cataract surgery combined with filtration surgery.

or combined cataract/glaucoma surgery should be considered.

Robert L. Stamper, MD, is Professor of Clinical Ophthalmology and Director of the Glaucoma Service at University of California, San Francisco.

## REFERENCES

1. Heffelfinger BL, Berman MN, Krupin T, et al. Surgical management of coexisting glaucoma and cataract. *Ophthalmol Clin North Am.* 2000;13:545-52.
2. Jahn CE. Reduced intraocular pressure after phacoemulsification and posterior chamber intraocular lens implantation. *J Cataract Refract Surg.* 1997;23:1260-4.
3. Shingleton BJ, Pasternack JJ, Hung JW, O'Donoghue MW. Three and five year changes in intraocular pressures after clear corneal phacoemulsification in open angle glaucoma patients, glaucoma suspects, and normal patients. *J Glaucoma.* 2006;15(6):494-8.
4. Damji KF, Konstas AG, Liebmann JM, et al. Intraocular pressure following phacoemulsification in patients with and without exfoliation syndrome: a 2 year prospective study. *Br J Ophthalmol.* 2006 Aug;90(8):1014-8.
5. Lai JS, Tham CC, Chan JC. The clinical outcomes of cataract extraction by phacoemulsification in eyes with primary angle-closure glaucoma (PACG) and co-existing cataract: a prospective case series. *J Glaucoma.* 2006;15(1):47-52.
6. Liu CJ, Cheng CY, Wu CW, et al. Factors predicting intraocular pressure control after phacoemulsification in angle-closure glaucoma. *Arch Ophthalmol.* 2006;124(10):1390-4.
7. Jacobi PC, Dietlein TS, Lüke C, et al. Primary phacoemulsification and intraocular lens implantation for acute angle-closure glaucoma. *Ophthalmology.* 2002;109(9):1597-603.

Additional references for this article can be found on [www.GlaucomaTopics.com](http://www.GlaucomaTopics.com)

## COMING IN ISSUE 11:

### PEDIATRIC GLAUCOMA

- **FEATURE:** Childhood Glaucoma: The Challenge
- **UPDATE:** Genetics of Childhood Glaucoma
- **CLINICAL FOCUS:** Pediatric Management Issues
- **IN PRACTICE:** Wider Issues

## FUTURE ISSUES

ISSUE 12: *Screening and Case Detection*

ISSUE 13: *The Patient's Perspective*

ISSUE 14: *Progression of Visual Function Loss*

### Stamper Overset:

8. Tran HV, Liebmann JM, Ritch R: Iridociliary apposition in plateau iris syndrome persists after cataract extraction. *Am J Ophthalmol.* 2003;135(1):40-3.
9. Rainer G, Menapace R, Schmid KE, et al. Natural course of intraocular pressure after cataract surgery with sodium chondroitin sulfate 4%-sodium hyaluronate 3% (Viscoat). *Ophthalmology.* 2005;112(10):1714-8.
10. Rainer G, Schmid KE, Findl O, et al. Natural course of intraocular pressure after cataract surgery with sodium hyaluronate 1% versus hydroxypropylmethylcellulose 2%. *Ophthalmology.* 2007;114(6):1089-93.
11. Levkovitch-Verbin H, Habot-Wilner Z, Burla N, et al. Intraocular pressure elevation within the first 24 hours after cataract surgery in patients with glaucoma or exfoliation syndrome. *Ophthalmology.* 2008;115(1):104-8.
12. O'Brien PD, Ho SL, Fitzpatrick P, Power W. Risk factors for a postoperative intraocular pressure spike after phacoemulsification. *Can J Ophthalmol.* 2007;42(1):51-5.
13. Friedman DS, Jampel HD, Lubomski LH, et al. Surgical strategies for coexisting glaucoma and cataract: an evidence-based update. *Ophthalmology.* 2002;109(10):1902-13.
14. Mathalone N, Hyams M, Neiman S, et al. Long-term intraocular pressure control after clear corneal phacoemulsification in glaucoma patients. *J Cataract Refract Surg.* 2005;31(3):479-83.

### GREHN Overset:

15. Rosetti L, Bucci L, Miglior S, et al. Temporal corneal phacoemulsification combined with separate incision superior trabeculectomy versus standard phacotrabeculectomy; a comparative study. *Acta ophthalmol Scand Suppl.* 1997;224-39.
16. Shingleton BJ, Price RS, O'Donoghue MW, et al. Comparison of 1-site versus 2-site phacotrabeculectomy. *J Cataract Refract Surg.* 2006; 31:799-802.
17. Verges C, Cazal J, Lavin C. Surgical strategies in patients with cataract and glaucoma. *Curr Opin Ophthalmol.* 2005;16(1):44-52.
18. Weitzman M, Caprioli J. Temporal corneal phacoemulsification combined with separate-incision superior trabeculectomy. *Ophthalmic Surg.* 1995;26:271-73.
19. Wyse T, Meyer M, Ruderman JM et al. Combined trabeculectomy and phacoemulsification; a one-site vs a two-site approach. *Am J Ophthalmol.* 1998;125: 334-39.